

See discussions, stats, and author profiles for this publication at: <https://www.researchgate.net/publication/349091037>

Role of Lingual Splint in prevention of Mandibular flaring in Management of Mandibular fracture

Article · February 2021

CITATIONS

0

READS

26

3 authors, including:



Hamada Fadi

Benha University

12 PUBLICATIONS 0 CITATIONS

SEE PROFILE

Role of Lingual Splint in prevention of Mandibular flaring in Management of Mandibular fracture

Mohamed El sayed Hassan, Hamada Fadl Hashem, Ayman Abdel aal Mohamady

Abstract

Introduction

For the past decades, there has been a significant increase in head-maxillo-facial traumas, and mandible fracture occupies the second most frequent incidence of facial bone fractures, with incidence of about 38%. They are mainly caused by Road traffic accidents (RTA).

Aim

To study the effect of repairing the parasymphseal mandibular fractures with rigid fixation alone versus usage of lingual splint with rigid Fixation as regard occurring of mandibular flaring.

Patients and methods

A prospective randomized clinical study carried out in Benha University Hospital, Included 30 patients who suffered from isolated parasymphseal mandibular fracture. Patients were allocated into two groups; **A** (15 Patients underwent rigid fixation of parasymphseal mandibular fracture) and **group B** (15 Patients underwent rigid fixation of parasymphseal mandibular fracture with usage of lingual splint).

Results

Our study showed that in group (B) the mean bigonial width and bicondylar breadth were lower than that in group (A), this differences were statistically significant at 3 months after operation but there were not significant between both groups in the pre-operative time and just after operation. As regard complications, there were no significant differences between two groups as regard intra and post-operative complications

Conclusion

Adding lingual splint as adjuvant to rigid fixation will offer more stability and accuracy for reduction and prevent occurring of lingual splay of fracture fragments and mandibular angle flaring with subsequent minimize effect on tempromandibular joint.

Keywords: Lingual splint, Fracture Mandible, Rigid fixation, Mandibular flaring, Tempromandibular disorders.

Introduction

In the past decades, head-maxillo-facial traumas, and mandible fracture showing a significant increase being the second most frequent incidence of facial bone fractures, with incidence of about 38%. They are mainly caused by car accidents because it is a resistant bone that needs strong blow to be fractured, which can also be a consequence of sport activities, firearm or sharp accident, physical assault, work-related accident, metabolic diseases or tumors⁽¹⁾.

Innovations in the management of cranio-maxillofacial trauma have continued to evolve, the introduction of rigid internal fixation provides advancement in the treatment of facial fractures by optimizing primary bone healing, in comparison to secondary bone healing seen with closed techniques⁽²⁾.

Fractures of mandible have many categories. According to location: Symphysis, parasym-physis, body, angle, ramus, condylar, coronoid and dentoalveolar.

Also the fracture patterns may be open, closed, greenstick, comminuted, pathologic or complex (complicated).

According to biomechanics mandibular fracture displacement may be stable or unstable. Fractures of mandible can be diagnosed by physical examination where signs and symptoms of mandiblar fractures include: pain, swelling, paraesthesia, trismus, malocclusion, ecchymosis, gingival laceration, mobility of bone segments, palpable bony steps, and deviation of mandible.

The treatment techniques could be closed using arch bars, intermaxillary fixation screws (IMF), interdental wire fixation, skeletal suspension wires,

various bonded and non-metallic tooth borne systems or Open include: semi rigid fixation using miniplates and monocortical screws or rigid fixation using nonlocking plates/screws, locking plates/screws which are either threaded locking screws or tapered locking screws. The lag screw technique was introduced to oral and maxillo-facial surgery by bronson and boering in 1970. Lag screw fixation has been commonly used to compress fracture fragments without use of bone plates⁽³⁾.

Miniplates (semi-rigid) fixation was introduced at 1978. The use of mini plates placed along line of osteosynthesis has been demonstrated to be effective treatment modality. Over decades there were many modifications in the technique using Trans oral and trans buccal approaches. Case selection is of a most importance in order for this technique to be effective. It is not recommended in cases that lack adequate buttressing of bone or doubtful patient compliance⁽⁴⁾.

Strategy for treatment of maxillofacial fracture involves restoring normal function, maintaining normal occlusion, and preventing facial deformities. To achieve these objectives, maxillofacial surgeons must reduce, fixate, and retain in position anatomically aligned bone fragments should be long enough to allow for bony union. The lingual splint is frequently used in the treatment of symphysis fractures to prevent inward tilting of the alveolar ridge and to counteract the tendency of the inferior border to become distracted⁽⁵⁾

Fortunately, most patients do not have long-term negative sequelae because of closed reduction techniques. The temporo-mandibular joint is a site of alteration that may lead

to permanent changes of structure and function. These changes included but are not limited to stiffness of the joint and limited opening, atrophy/denervation of muscles, loss of bite strength and range of motion, and change in cartilage structure internally in the joint ⁽⁶⁾.

Aim of the Work:

To study the effect of repairing the parasymphsial mandibular fractures with rigid fixation alone versus usage of lingual splint with rigid Fixation as regard occurring of mandibular flaring.

Patients and Methods:

This study was conducted at Otorhinolaryngiology Department in Benha University Hospital. Included 30 patients, age above 20 years old, divided into two groups:

- Group A: 15 Patients underwent rigid fixation of parasymphseal mandibular fracture.
- Group B: 15 Patients underwent rigid fixation of parasymphseal mandibular fracture with usage of lingual splint.

All cases suffered from isolated parasymphseal mandibular fracture with history of different patterns of traumatic causes indicated for rigid fixation of maximum 1 month duration with no multiple mandibular fractures or history of mandibular fixation operation. None of them had neurological, cervical spine or other system injury.

The mode of trauma was road traffic accident (RTA) in (50%) of cases other causes were fall (accidental) in (23.3%) of cases and other causes in (26.7%) e.g. industrial, assault, sports.

❖ Diagnosis:

☒ History taking:

- *Personal History.*
- *History of Present Illness:*

Onset, Course, Duration, the mechanism of injury, including the direction of the force, whether there is any complaint of malocclusion, and whether there is any associated pain, especially in the cervical spine and associated symptoms of other systems.

- *Past History.*

☒ Clinical examination:

- *1ry survey (ABCDE).*
- *2ry survey.*
- **Local examination:**

The physical exam included an assessment from the skull to the clavicles for soft tissue injuries, ecchymosis, pre auricular swelling, hematoma and asymmetries, as well as midline structures including the larynx and trachea. Neck zones I to III examined for penetrating trauma, crepitus, and hematoma.

The mandible and lower facial third examined and palpated for mobility, mucosal lacerations, fractured or avulsed teeth, malocclusion, bony steps or discontinuity, and any hematomas/ecchymosis of the floor of the mouth

Bimanual manipulation of the mandible to assess for fracture mobility, assessment of symmetry and deviation upon mouth opening, maximal interincisal opening, and evaluation of the dentition for avulsion of teeth and/or dentoalveolar fractures

Examination of the condyles mobility or tenderness in preauricular area to exclude condylar or subcondylar fracture.

Evaluation of neurosensory disturbance in the distribution of the

inferior alveolar nerve/mental nerve.

☒ **Investigations:**

- 1- **C.T facial bone (coronal, axial):** with reconstructed 3D view of the mandible and slice thickness of 1–3 mm (**Figure 1**).
- 2- **Preoperative panoramic X-ray Orthopantograph (OPG) done** (**Figure 2**).

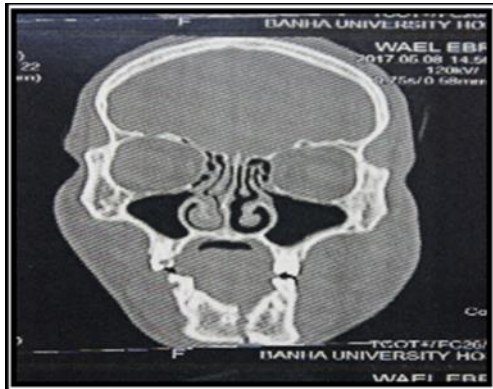


Fig 1: CT scan; Parasymphyseal fracture with minimal displacement.

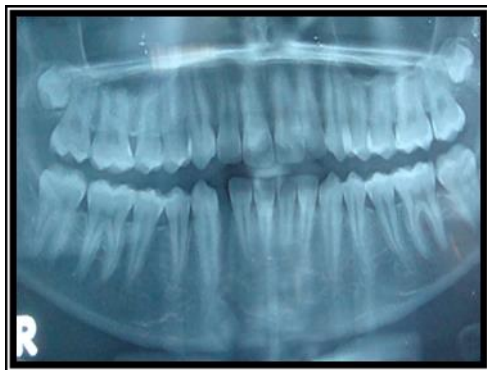

Fig 2: Panoramic graph showing Parasymphyseal fracture.

Every patient CT imaging was evaluated considering the following axes:

- Intergonial width (taking as a reference): the most prominent part of the lower edge of the mandibular ramus on both sides

- Intercondylar breadth: (taking as a reference): the lateral poles of both mandibular condyles.
- And these axes were measured by using Mimics 17 program.

❖ **Treatment:**

☒ **Preoperative:**

- Although road traffic accident were accounted for as a cause of injury for 50% of this group, none of them had major vital signs instability, CNS, cervical spine injury, abdominal or any other important system injury.
- Ten patients had chin cut wounds that were sutured in emergency room.
- Seven patients had cheek cut wound.
- Lab tests ordered based on information obtained from the history and physical exam.
- All patients signed an informed consent form acknowledging that they are aware of risks and complications, that they know they will be receiving anesthesia, and that we has explained the operation to them.
- All patients had instructed to discontinuing prescription and over-the-counter medications that "thin" the blood, such as aspirin prior to surgery. Patients who took prescription medications on a regular basis discussed this with us.

Treatment of mandibular fractures:

Group A:

The basic aim is to reduce and fix the bone ends in all of cases; functional

reduction has been restored through MMF (Erich arch bars) (**Figure 3**).

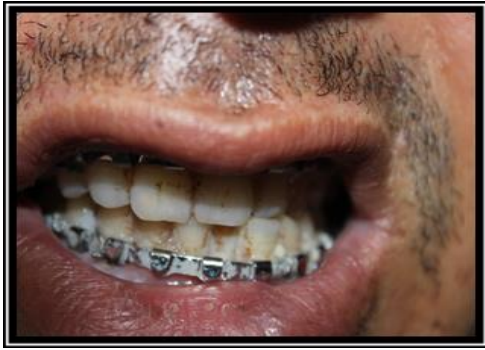

Fig 3: Arch bar used for MMF and improper occlusion

Surgical technique; Mandibular intra-oral approach:

Skin Preparation at surgical site as dirt and skin oils are removed with scrubbing action and antiseptic agents were used (Betadine) and draping on surgical site and this was accomplished by the circulating nurse who wears sterile gloves and mask.

Injection of local anathesia and vasoconstrictor agents at the site of incision and this for a hemostatic rule (**Figure 4**).

Exposure to parasymphysis and symphysis Done via genioplasty incision, high mucosal incision in the area of premolar, 4mm below the attached gingiva to get a good cuff of mucosa for closure of the incision to prevent occurring of dehiscence and continue in arc shape in the midway between the vermilion border of the lip and the level of free gingiva in the anterior lower incisor (**Figure 5**).

Dissection of mucosa from mentalis muscle for about 1 c.m then second incision obliquely directed to the lower border of the mandible (**Figure 6**), this will allow much more attachment to the mentalis muscle to prevent dropping of the lower lip, subperiosteal dissection to connect the two ends in

the area of premolar dissection is done from up to down motion to identify, dissect the mental nerve. Sometimes we need skeletonization of the mental nerve to avoid traction on it.

Anatomical reduction through approximating of the two bone ends then fixation by Two-plate technique (superior monocortical tension band 2mm miniplate and inferior border bicortical compression plate 2.3 mm, **figure 7**) after anatomical and fuctional reduction, holes are drilled in each sides of fracture using 1.5 mm diameter drill and application of 9mm-13mm screw inside 1mm miniplates with minimum of two holes in each end.

The two-plate technique uses a superior tension band, low-profile/miniplate to prevent fracture distraction at the alveolar process level, while a more rigid intermediate-profile plate (reconstructive plate 2.3 mm) is placed in the compression zone at the inferior border. The superior border plate is a monocortical plate respecting the local dental anatomy. The inferior border plate is fixated with bicortical screws to maintain rigidity, immobility, and fracture reduction (**Figure 8**).

Closure is done in layer:

- Mentalis muscles, by one suture in midline then suturing each muscle (**Figure 9**).
- Mucosa, continous sutures were used using 3/0 vicryle suturing material (**Figure 10**).

In all these cases, visualization, access to the fracture sites and handling of fracture segments were done without special difficulties.

No specific complications for the approach (mental nerve injury, injury to roots of the teeth, injury to facial

vessels and facial muscles malfunction) had occurred.

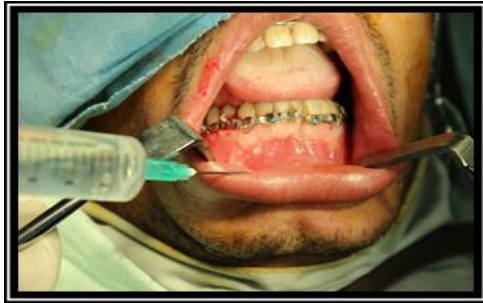

Fig 4: Local anesthesia and vasoconstrictor infiltration.

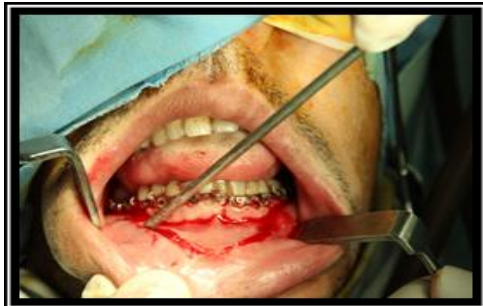

Fig 5: Arc shape incision

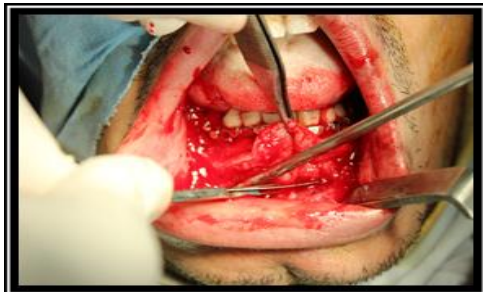

Fig 6: Mentalis muscle dissection

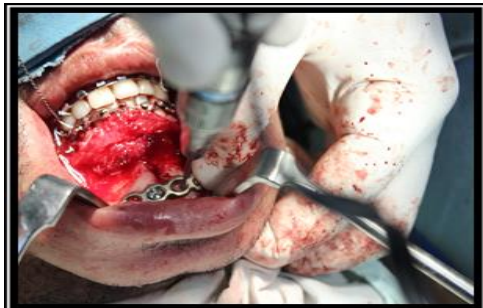

Fig 7: Fixation of 2.3 reconstructive

plates

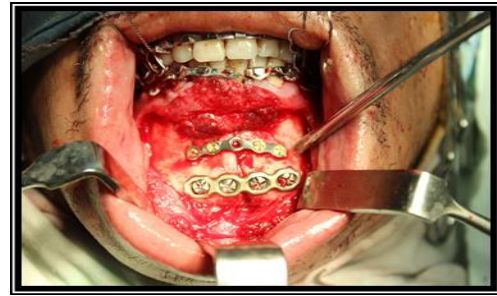


Fig 8: Two plate technique

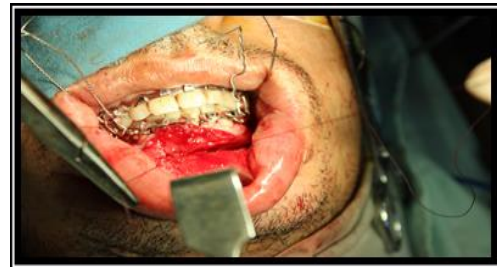

Fig 9: Closure of mentalis muscle.

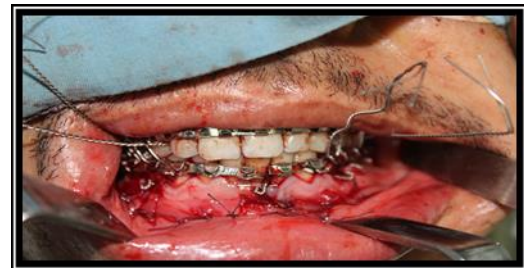

Fig 10: Wound after complete closure with suturing.

Group B:

The same technique as Group A was applied on Group B (**Figure 11**).

- MMF via (Erich arch bars)
- Exposure to parasymphysis and symphysis Done via genioplasty incision
- Dissection of mucosa from mentalis muscle
- Then Lingual Splint Fixation was done as the difference between two groups.

- Fixation by Two-plate technique
- 3/0 vicryle suturing

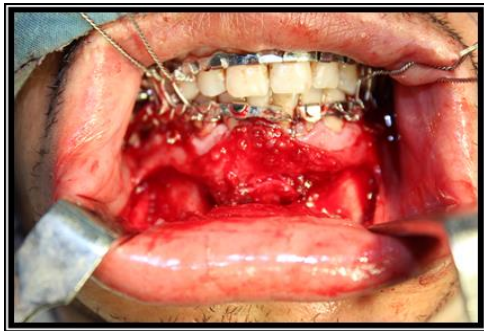


Fig 11: Exposure of fracture line after MMF via (Erich arch bars).

Lingual splint construction:

- The initial requirement in the fabrication of a lingual splint is obtaining an accurate impression of the patient's mandibular and maxillary arches. Alginate is used to take dental impressions. Binding of alginate with water forms a viscous gum, which is able to mold the surfaces of the teeth which occurring at the laboratory dentiform.
 - The patient should be seated in a chair in a relaxed forward position and instructed to breath slowly through his or her mouth after the tray is inserted. The setting time for the impression material is approximately 3 min, or when it becomes firm and rubbery. The tray may be easily removed after the impression material has set by pushing down posteriorly on one side with a finger to break the suction seal. Once removed, the tray is wrapped in a moist towel (and possibly placed in a plastic bag) until it is ready to be used. The impression of the other jaw is done next and placed with the first impression.
 - Dental stone or plaster is poured into the impressions to create models of the dental arches. Pouring dental stone (Hydrocal) or plaster of Paris into the alginate trays creates the plaster models (**Figure 12**).
- The models were sent to the lab to reconstruct a heat cured acrylic splint after creation of anormal occlusion on articulators (**Figure 13**).
- Stabilization of the splint is achieved by circumdental fixation. It is important that the splint is ligated below the height of the contour of the teeth. If not, circumdental wires may become unstable and the splint displaces occlusally (**Figure 14**).
 - ensure postoperative x-ray, antibiotic, mouth wash and soft diet.
- ❖ Follow up radiographic examination:
- Follow up C.T was done by all patients at 0, 3 months and the mandibular width was evaluated considering the following axes:
- Intergonial width: taking as a reference the most prominent part of the lower edge of the mandibular ramus on both sides
 - Intercondylar breadth: taking as a reference the lateral poles of both mandibular condyles. And these axes were measured by using Mimics 17 program.
 - Immediate postoperative results showed properly reduced fracture segment with no interfragmentary gap in both groups.
 - Clinical examination to test mobility, deformity, infection or

malocclusion was done in each visit

Example: case 1 showed in figure 15 and case 2 showed in figure 16.

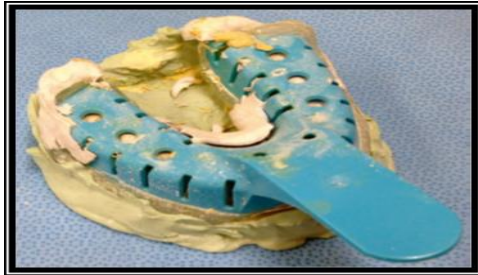


Fig 12: Creation of upper and lower models.

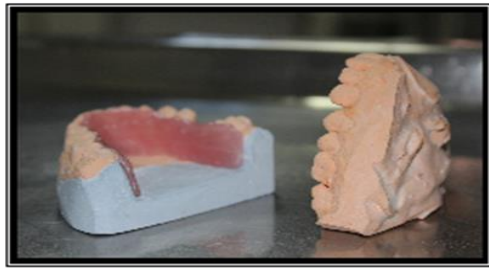

Fig 13: Lingual splint on the cast.

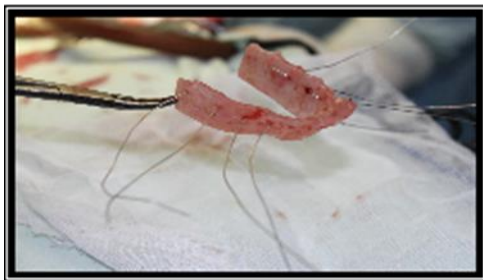
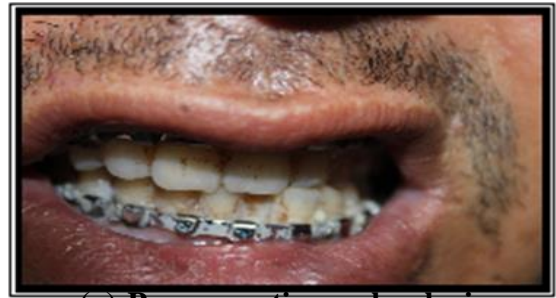
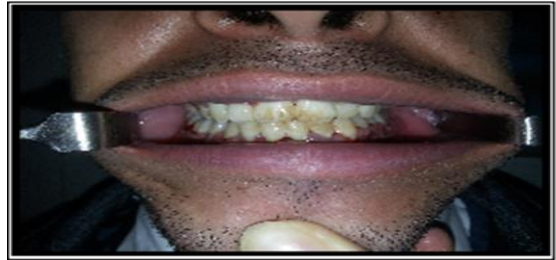
Fig 14: Lingual splint before fixation.

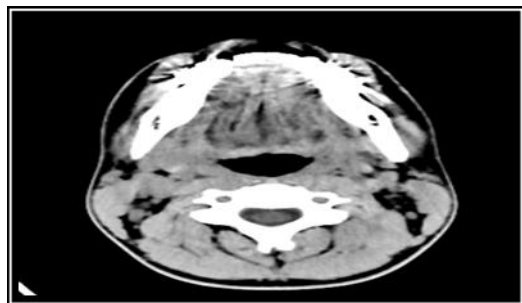


(a):Pre- operative malocclusion

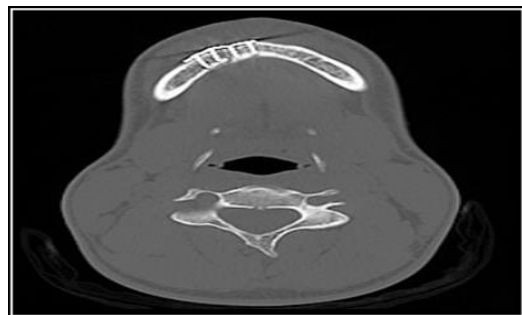


(b): Proper occlusion three months after operation for a patient managed with lingual splint with rigid fixation.

Fig 15 (a&b): Case 1



(a): Pre-operative axial CT.



(b): Post-operative axial CT

Fig 16 (a&b): Case 2

Results

➤ Demographic characteristics in both study group:

This table shows the relation between both groups regards age and sex, the mean age in group A was 21 y and 24 y in group B, per cent of male was 66.6 and 73.3 in both groups A and B respectively, per cent of females was 33.3 and 26.7 respectively.

There were no significant differences between both groups as regard age and sex. P values were 0.539 and 1.0 respectively (**Table 1**).

Table 1: Demographic characteristics in both study groups

Age (years)	Group A (n = 15)	Group B (n = 15)	P value
Mean ±SD	21 ±1	24 ±5	0.539
Gender			
Males n (%)	10 (66.7)	11 (73.3)	1.0
Females n (%)	5 (33.3)	4 (26.7)	1.0

➤ Pattern of trauma in both study group

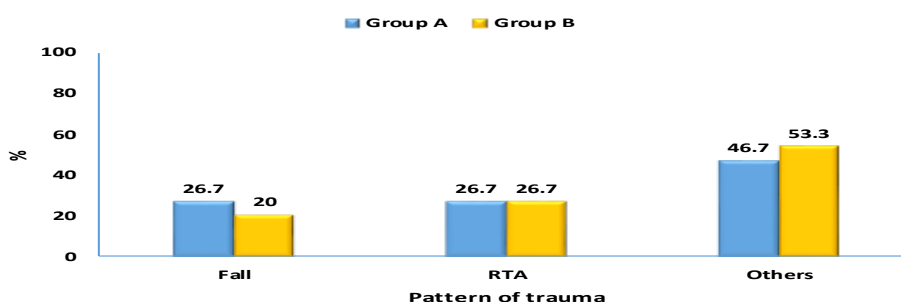
This table shows frequency distribution of Pattern of trauma in both study group, per cent of RTA as a cause was 46.7 and 53.3 in group A and B respectively, per cent of fall was 26.7 and 20, per cent of other causes was 26.7 and 26.7 respectively.

There was no significant difference between both groups as regard pattern of trauma. P value = 1 (**Table 2 and Figure 17**).

Table 2: Frequency distribution of Pattern of trauma in both study groups

Pattern of trauma	Group A (n = 15)		Group B (n = 15)		P value
	N	%	N	%	
Fall	4	26.7	3	20.0	1.0
Others	4	26.7	4	26.7	
RTA	7	46.7	8	53.3	

Fig 17: Frequency distribution of pattern of trauma in both groups



➤ **Pre-operative, post-operative and after 3 months bigonial width in both study group**

❖ **Pre-operative**

Mean of bigonial width was 94.59 in group A and 96.05 in group B.

There was no significant difference in bigonial width between both groups. P value = 0.126

❖ **Post-operative**

Mean of bigonial width was 91.87 in group A and 92.31 in group B.

There was no significant difference in bigonial width between both groups. P value = 0.126

❖ **At 3 months**

Mean bigonial width was higher in group A (92.65) than that in group B (89.94).

This difference was statistically significant. P value <0.001 (**Table 3**)

Table 3: Bigonial width preoperative, post-operative and at 3 months.

Bigonial width	Group A (n = 15)		Group B (n = 15)		P value
	Mean	±SD	Mean	±SD	
Pre-operative	94.59	2.84	96.05	1.45	0.126
Post-operative	91.87	2.38	92.31	0.48	0.126
At 3 months	92.65	2.08	89.94	0.69	<0.001

➤ **Pre-operative, post-operative and after 3 months bicondylar breadth in both study groups**

This table shows mean and SD of bicondylar breadth preoperative, post-operative and at 3months after operation in both groups and comparison between them.

❖ **Pre-operative**

Mean of bicondylar breadth in group A was 116.26 and 117.05 in group B

There was no significant difference in bicondylar breadth between both groups. P value = 0.081

❖ **Post-operative**

Mean of bicondylar breadth in group A was 112 and 112.7 in group B.

There was no significant difference in bicondylar breadth between both groups. P value = 0.126

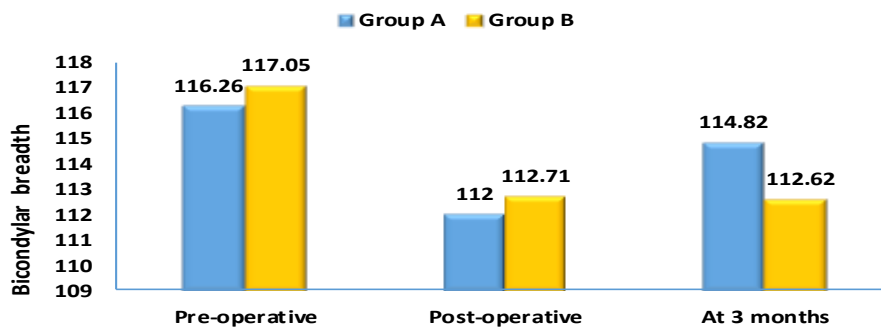
❖ **At 3 months**

Mean bicondylar breadth was higher in group A (114.82) than that in group B (112.62). This difference was statistically significant. P value = 0.029 (**Table 4 and Figure 18**)

Table 4: Bicondylar breadth preoperative, post-operative and at 3 months.

Bicondylar breadth	Group A (n = 15)		Group B (n = 15)		P value
	Mean	±SD	Mean	±SD	
Pre-operative	116.26	0.85	117.05	1.3	0.081
Post-operative	112	1.21	112.71	3.07	0.126
At 3 months	114.82	0.81	112.62	4.15	0.029

Fig 18: Pre-operative, post-operative and at 3months bicondylar breadth in both groups



➤ **Complications**

Table 5 shows comparison between both groups regards complication. Percent of decreased range of motion for 1w duration after operation and edema was 26.7 in group A and 20 in group B. Parathesia or numbness (1W), malnutrition and loss of loose teeth 13.3% in both groups

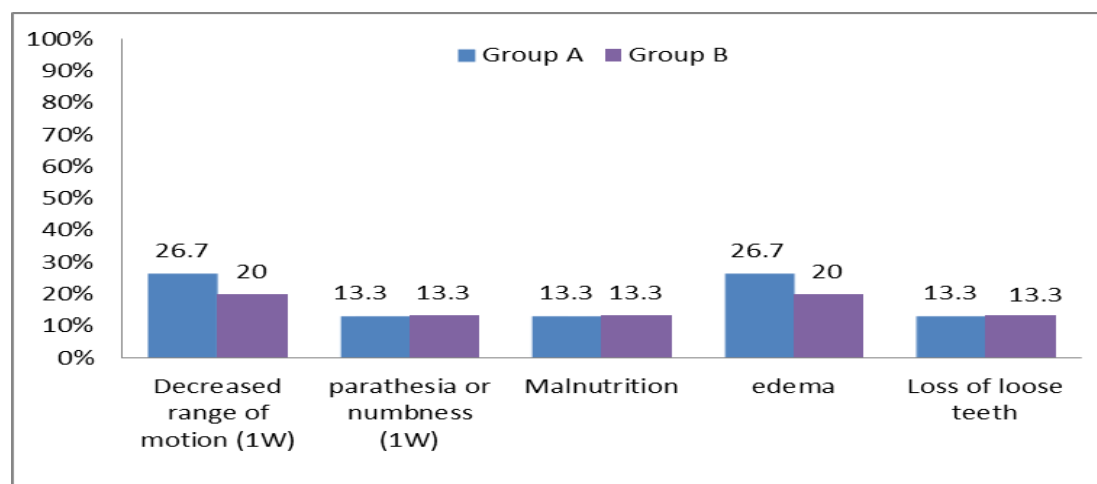
As regard complications, there were no significant differences between two groups as regard intra and post-operative complications, decreased range of motion (for 1W duration), Parathesia or numbness (for 1W duration), malnutrition, loss of loose teeth and Edema. Also, decreased range of motion during first weak after operation and edema noticed to be the most common complication in both groups

(Table 5 and figure 19).

Table 5: Comparison between the two groups regards complications

Complication	Group A (n = 15)		Group B (n = 15)		P value
	N	%	N	%	
Decreased range of motion (1W)	4	26.7	3	20.0	1.0
Parathesia or numbness (1W)	2	13.3	2	13.3	1.0
Malnutrition	2	13.3	2	13.3	1.0
Edema	4	26.7	3	20.0	1.0
Loss of loose teeth	2	13.30	2	13.3	1.0

Fig 19: Comparison between the two groups regards complications



Statistical methods

Data management and statistical analysis were done using SPSS vs.25. Numerical data was summarized using means and standard deviations. Categorical data was summarized using numbers and percentages. Comparisons between both groups were done using Mann Whitney U test for numerical variables. Categorical variables were compared using Chi-square test or Fisher exact test if appropriate. All P values were two sided. P values less than 0.05 were considered significant.

Discussion

Lingual gap occur due to improper reduction of fragments in symphyseal and parasymphyseal fractures, causing transverse and longitudinal dimensional changes and a subsequent increase in facial width⁽⁷⁾.

The use of lingual splints provides simple reduction and fixation of sagittal mandibular fractures, especially those which are displaced lingually⁽⁸⁾.

There were no significant differences between both study groups as regard age in this study. Mean age was 22.3y in both groups, this was consistent with **Natu et al., 2012**⁽⁹⁾ who found that the incidence of parasymphyseal mandibular fracture which was the commonest site in his study increased with increasing age from 0 to 30 years then progressively decreased from 31 years of age. Also consistent with **John et al., 2010**⁽¹⁰⁾ who reported that mandibular fractures are relatively less frequent in children in comparison to adults, this is due to protective anatomic features of children and infrequent exposure of children to alcohol related traffic accidents. Also **Barde et al., 2014**⁽¹¹⁾ found that the highest incidence of mandibular fractures is found in the age group of 21–30 years, This is due very high use of two-wheelers, early bikers, lack of safety measures in the form of helmets and improper road conditions, as most of fractures in this group belong to RTAs.

Although There were no significant differences between both study groups as regard sex, percent of males was bigger than percent of females in both groups male: female ratio was 2.3: 1. **Barde et al., 2014**⁽¹¹⁾ shows that there was male dominance of the gender distribution revealed a male: Female ratio of approximately 3.7: 1 in

contrast to study by **Subhashraj et al., 2008**⁽¹²⁾ That shows an increasing trend of female involvement in maxillofacial trauma. The reasons may be related to increased mobility and social engagements of females. The male dominant culture is being shifted to work culture where men as well as women are getting equal opportunities.

Also our study showed that there was no significant difference between both groups as regard pattern of trauma either falls, RTA or other causes; but RTA was the most common cause of fracture in both groups it was 15 cases out of 30. Adults between the age group of 21 and 50 years were mainly victims of RTA whereas those over age 50 suffered fractures from falls. There is amajor difference in the etiology of maxillofacial trauma in developing and developed nations. The common cause of maxillofacial trauma in developing countries is RTAs, while assault is the most common cause in developed countries.

Barde et al., 2014⁽¹¹⁾ findings also support the same, as 68% of their patients; RTA was the cause of injury, the parasymphyseal fractures were found to be most common in RTAs. Our findings also support the same results. While (**Dongas and Hall, 2002**)⁽¹³⁾ and (**Olasoji et al., 2002**)⁽¹⁴⁾ reported assault as the maincause.

Our study showed that in group (B) the mean bigonial width was lower than that in group (A), this difference was statistically significant at 3 months after operation but there was not significant between both groups in the preoperative time and just after operation.

Also the same results regarding bicondylar breadth, the mean bicondylar breadth was lower in group (B) than that in group (A) This difference was statistically significant

at 3 months after operation but there was no statistically significant difference between both groups in the preoperative time and just after operation.

Patients who underwent rigid fixation of parasymphseal mandibular fracture with use of lingual splint have lower bigonial and bicondylar width than patients who underwent rigid fixation only, this difference noticed after 3 months of operation, which means that adding lingual splint as adjuvant to rigid fixation will offer more stability and accuracy for reduction and prevent occurring of lingual splay of fracture fragments and mandibular angle flaring with subsequent effect on temporo-mandibular joint.

Miniplates are the commonly used implants to achieve osteosynthesis in mandibular fractures. However, the major limitations of using miniplates in sagittal fractures are (1) inability to check the anatomic reduction on the lingual aspect intraoperatively, and (2) inability to prevent lingual splay and torsional forces during fixation.

In such situations, lingual splints may be an important method of achieving the interfragmentary reduction, especially in the buccolingual direction. The wires of the lingual splint when tightened, achieve fracture reduction in comparison to the use of lag screw technique, as demonstrated by the clinical cases **Schouman et al., 2015**⁽¹⁵⁾ and that was consistent with our results.

Our study findings are consistent with the results obtained by **Balasubramanian et al., 2017**⁽¹⁶⁾ who mentioned that the role of lingual splints in sagittal fractures of the mandible is noteworthy. They serve as a simple but effective adjunct to

fracture reduction, before semirigid (miniplates) or rigid (lag screws) fixation, especially to prevent lingual splay of fracture fragments. However, its use affected by the time and cost of preparation.

Romeo et al., 2013⁽¹⁷⁾ had reported that the use of lingual splints have some limitations such as additional time and expensive preoperative laboratory work for splint fabrication, but that was inconsistent with our experience during preoperative preparation as fabrication of lingual splint didn't represent more financial burden for patient.

In fact, lingual splints offer many advantages; they improve the precision in achieving anatomic reduction of the fracture. In addition to permitting verification of the accuracy of dental occlusion intra-operatively, and also reduce the intraoperative time for fracture reduction. However, our study did not record the time objectively and a randomized controlled trial comparing the time taken for reduction of fractures with or without splints might provide accurate data regarding the same.

The greatest advantage of the lingual splint is that the model surgery performed before splint fabrication permits the surgeon to visualize how the fractured components of the mandible need to be rotated, to establish the reduction of the fractures. The splint also stabilize the fractured segments, preventing rotation during the application of rigid plate in screwfixation⁽¹⁸⁾.

On the other hand, the lingual gap created by parasymphseal fractures is directly proportional to the transverse mandibular dimension.

The Mimics 17 program that we used for measuring dimensions in our study does not allow one to represent

the interaction between the jaw and the muscles at work, the behavior of soft tissue, and the behavior of the joint capsule, all of which restrict lateral expansion on the part of the mandibular rami and condyles. In spite of this limitation, the fact that a discrepancy between lingual cortical plates creates a relevant increase in the intergonial and intercondylar distances, consequently increasing the posterior facial width, can nevertheless be extrapolated to clinical practice.

Thus, with parasymphyseal fractures in which there are no concomitant compromises to the mandibular condyles, a clear widening of the mandibular angulation is produced, but the mandibular condyles move less, as they are surrounded by the joint capsule, which limits lateral movement. However, a discrepancy is still produced, in which the condylar surface loses its relationship with the temporal fossa, causing a functional alteration of the temporomandibular joint that will have an impact on the entire stomatognathic system, creating a discocondylar alteration and, eventually, degenerative disease of the joint surfaces.

The key point to prevent a lingual gap after parasymphyseal fractures is to restore the transverse bigonial dimension through proper reconstruction of the mandibular arch⁽¹⁹⁾.

Also findings of Ellis and Tharanon's at 1992 were consistent with the results of our study, they mentioned that rigid internal fixation devices alone can easily generate mandibular widening. This means that a small mistake in the reduction produces a major change in the position of the mandibular ramus and even the IMF with wires in the buccal surface of the teeth or fixation by means of arches, which tilts the

mandibular segments lingually⁽²⁰⁾.

They mentioned different alternatives to avoid creating a lingual gap with parasymphyseal fractures and thus also dimensional alterations in the jaw, proposed using wire or intermaxillary arch fixation, which thought to apply digital pressure in the area of the gonial angles to eliminate the lingual gap while at the same time attaining proper interdigitation of the teeth.

Regarding the technique used to visualize the fracture site we prefer to use an intraoral approach, such as an extended lower vestibulotomy, as well as a genioplasty procedure in which the entire basilar edge is peeled back until access to the lingual plate has been gained, thus allowing direct visualization of the proper setting of the fracture tips in the lingual plate.

The most important factor to ensure proper reduction of parasymphyseal fractures is to visualize an adequate setting of the lingual cortical plates. Although the indirect view makes it hard to visualize the proper setting of the lingual plates, obliging the use of an endoscope or mirror as some authors recommended, we used the lingual splints to adjust the fracture lines at the lingual cortical aspects which allowing us to dispense with the usage of the mirror and endoscope.

Therefore, an alternative is an extraoral submental approach or mandibular degloving that expands the surgical field and allows a direct view of the lingual plate, unless there is an injury in the submental region that allows access.

Some authors propose that, when faced with parasymphyseal fractures and when there is no adequate access allowing a view of the lingual cortical plates, one must evaluate the possibility of opening a submental

approach, assessing its advantages and disadvantages and considering that the complications caused by inadequate reduction in these types of fractures lead to increased morbidity, making it difficult to intervene again when facial proportions are altered.

As regard complications, there were no significant differences between two groups regard intra and post-operative complications, decreased range of motion (for 1W duration), parathesia or numbness (for 1W duration), malnutrition, loss of loose teeth and edema. Also, decreased range of motion during first weak after operation and edema noticed to be the most common complication in both groups.

Moreno et al., 2000 ⁽²¹⁾ reported that the occurrence of postoperative complications like postoperative infection, and malocclusion, in the treatment of mandibular fractures is mainly related to the severity of the fracture rather than to the type of treatment used.

Chaurasia et al., 2015 ⁽²²⁾ mentioned that complications as deviation and crepitation were more common in fracture patients treated with miniplates compared to normal individuals with no history of fractures of the mandible and symptoms of TMD.

The presence of joint sounds as crepitation or grating sounds is usually a sign of degenerative joint disease. Imaging of the TMJ is necessary to confirm the degenerative changes of joint like resorption of bony surface as well as presence of osteophytes ⁽²³⁾.

Studies reported joint sounds and deviation on opening mouth in asymptomatic individuals. This could be the reason that some individuals in the control group had joint sounds and deviation on opening mouth although

they did not have any history of mandibular fracture or trauma to TMJ but the incidence was higher in mandible fracture group. This shows that trauma to the jaws resulting in fracture of mandible can lead to internal derangement and osteoarthritis of TMJ ⁽²⁴⁾.

Although four of our patients complained of TMJ crepitation and pain, but this was not the scope of our study. However, further studies and evaluation using MRI and CT scans as well as long-term follow up is required to exactly determine the relation between fracture mandible and its repair with different fixation techniques and occurring of changes on TMJ functions, and if it related to the severity of fracture or the type of treatment.

Conclusion:

Patients who underwent rigid fixation of parasymphial mandibular fracture with use of lingual splint have lower bigonial width and bicondylar breadth than patients who underwent rigid fixation only, this difference noticed after 3 months of operation, which means that adding lingual splint as adjuvant to rigid fixation will offer more stability and accuracy for reduction and prevent occurring of lingual splay of fracture fragments and mandibular angle flaring with subsequent minimize effect on tempromandibular joint.

Recommendations:

In treatment of parasymphaseal fracture, we recommend use of lingual splint as adjuvant to rigid fixation will offer more stability and accuracy for reduction and prevent occurring of lingual splay of fracture fragments and mandibular angle flaring.

Further studies and evaluation using MRI and CT scans as well as

long-term follow up is required to exactly determine the relation between fracture mandible and its repair with different fixation techniques and occurring of changes on TMJ functions.

References

1. **Patrocínio LG , Patrocínio JA, CarrijoBorba BH et al., (2005):** Mandibular fracture: analysis of 293 patients treated in the Hospital of Clinics, Federal University of Uberlândia, Brazilian Journal of Otorhinolaryngology , 71(5): 560–565 .
2. **Keles B, Ozturk, Arbag H et al., (2006):** Treatment options and common problems in patients with maxillofacial Trauma, Ulus Tra Vlna Acil Cerrahi Derg 12(3):218222.
3. **Domenick P Coletti, John F, Caccamesse (2009):** Diagnosis and management of mandible fracture, Oral and Maxillofacial Surgery Sec. Ed. Ch 10. P139.
4. **Champy M, Lodde JP, Schmitt R, et al. (1978):** Mandibular osteosynthesis by miniature screwed plates via a buccal approach, Journal of Oral and Maxillofacial Surgel Y 6(1):14-21.
5. **Charles C. Alling III, D.D.S, Donald B, Osbon, D.D.S (1988):** Maxillofacial Truma, Chapter 5: Maxillofacial Fracture Fixation Prosthesis, Methods, And Devices; 164 & 189.
6. **Meredith Blitz, DDSa, Kurt Notarnicola, DDSa (2009):** Atlas of The Oral and Maxillofacial Surgery Clinics, Chapter :Closed Reduction of the Mandibular Fracture , Page 12.
7. **Tiwana P, Kushner G, Alpert B (2007):** Lag screw fixation of anterior mandibular fractures: A retrospective analysis of intraoperative and postoperative complications. J Oral Maxillofac Surg 65: 1180.
8. **Kruchinsky H, Volkovets A (1991):** Comparative study of the treatment of mandibular fractures with vestibular and lingual wire splints. J Oral Maxillofac Surg; 49 (11): 1171–1175.
9. **Natu S, Pradhan H, Gupta H, Alam S, Gupta S, Pradhan R, Agarwal A (2012):** An epidemiological study on pattern and incidence of mandibular fractures. Plastic surgery international; 5 (2): 153–156.
10. **John B, John R, Stalin A, Elango I (2010):** Management of Mandibular Body fractures in pediatric patients: A case report with review of literature. Contemp Clin Dent J; 1 (4): 291-296.
11. **Barde D, Mudhol A, Madan R (2014).** Prevalence and pattern of mandibular fracture in central india.National journal of maxillofacial surgery,5(2),153.
12. **Subhashraj K, Ramkumar S, Ravindran C (2008):** Pattern of mandibular fractures in Chennai, India. Br J Oral Maxillofac Surg; 46: 126–7.
13. **Dongas P, Hall G (2002):** Mandibular fracture patterns in Tasmania, Australia. Australian Dental Journal, vol. 47, no. 2, pp. 131–137.
14. **Olasoji H, Tahir A, Arotiba G (2002):** Changing picture of facial fractures in northern Nigeria. British Journal of Oraland Maxillofacial Surgery, 40(2): 140–143.

15. **Schouman T, Rouch P, Imholz B, Fasel J, Courvoisier, D, Scolozzi P (2015):** Accuracy evaluation of CAD/CAM generated splints in orthognathic surgery: a cadaveric study. *Head Face Med*; 11: 24.
16. **Balasubramanian S, Panneerselvam, Sharma A, Singh V, Tatineni V, Raja K (2017):** Lingual Splint for Sagittal Fractures of Mandible; an Effective Adjunct to Contemporary Osteosynthesis: A Case Series with Review of Literature. *Cranio*. *Cranio* *Maxillofacial Trauma & Reconstruction Open*; 1 (1): e 9:e 14.
17. **Romeo G, Davies S, Costello B (2013):** A method for direct fabrication of a lingual splint for management of pediatric mandibular fractures. *Plast Reconstr Surg Glob Open*.1 (07): e51.
18. **Byron J, Kare H, Gerald B, (2001):** *Head and Neck Surgery: Otolaryngology*. 3rd ed. New Jersey, NJ: Lippincott Williams and Wilkins; 769–770.
19. **Gerbino G, Boffano P, Bosco G (2009):** Symphyseal mandibular fractures associated with bicondylar fractures: A retrospective analysis. *J Oral Maxillofac Surg* 67: 1656.
20. **Ellis E, Tharanon W (1992):** Facial width problems associated with rigid fixation of mandibular fractures: Case reports. *J Oral Maxillofac Surg*; 50: 87.
21. **Moreno J, Fernández A, Ortiz J, Montalvo J (2000):** Complication rates associated with different treatments for mandibular fractures. *Journal of oral and maxillofacial surgery*, 58 (3), 273-280.
22. **Chaurasia N, Guan J, Wang X, Sah G (2015):** Clinical analysis of changes in function of the temporomandibular joint after open reduction and internal fixation of mandible fracture. *Indian Journal of Oral Sciences*, 6 (2), 60.
23. **Cortes D, Exss E, Marholz C, Millas R, Moncada G (2011):** Association between disk position and degenerative bone changes of the temporomandibular joints: An imaging study in subjects with TMD. *Cranio*; 29: 117-26.
24. **Ribeiro R, Tallents R, Katzberg R, Murphy W, Moss M, Magalhaes A (1997):** The prevalence of disc displacement in symptomatic and asymptomatic volunteers aged 6 to 25 years. *J Orofac Pain*; 11: 37-47.